

Put Your Best Hand Forward

Amy Derick, MD



We have all heard the expression “Put your best foot forward.” People rarely form impressions about our age and health by looking at our feet because they usually are covered by shoes. Our hands, however, are always on public display—greeting others, making gestures, typing, dining, caressing—and people observe our hands nearly as often as our face when gauging our appearance. Nevertheless, the face seems to get more cosmetic attention than the hands, which usually are treated simply with lotions and nail polish. It is time for dermatologists to elevate their promotion of cosmetic treatment of the hands so patients can put their best hand forward.

On the hands, patients most commonly are concerned with superficial signs of aging, such as brown spots or other photodamaged discolorations, typically on the back sides of the hands. Fortunately, these discolorations can be easily treated with Q-switched lasers (Figure 1), intense pulsed light devices, cryosurgery, chemical peels, and photodynamic therapy. Skin laxity and wrinkles can be treated with ablative and nonablative fractional resurfacing devices. Bulging or prominent veins can be treated with sclerotherapy, phlebectomy, or endovenous vascular ablation.

Patients with volume loss of the hands may be candidates for injectables. Many patients are aware of injectable treatment options for the face from advertisements, but because hand rejuvenation is not a US Food and Drug Administration–approved indication for fillers, their use for this area is not advertised; therefore, dermatologists

must directly educate their patients about injectables for the hands. In my experience, few patients request injectables for their hands, but most patients are happy with the aesthetic outcome following treatment. Patients have responded particularly well to volume restoration to mask protruding tendons on the back of the hands. Injectables commonly used on the hands include hyaluronic acid, poly-L-lactic acid, calcium hydroxylapatite (Figures 2 and 3), and fat. (For more detailed information, a review of all hand rejuvenation articles published from 1989 to 2011 recently has been published.¹⁾

To increase patient awareness of hand rejuvenation treatments, dermatologists should, at a minimum, include these procedures in a cosmetic portfolio that is available for patients to view. During cosmetic consultations, the dermatologist or a member of the staff could describe the practice's full range of cosmetic options for the face, hands, and so forth. If your practice is marketing oriented, you could offer a hand rejuvenation package that includes laser treatment, injectables, and topical (cosmeceutical or prescription) products, thus patients will feel as though they are choosing cosmetic options for the hands rather than being pushed. Patients love to buy but dislike the feeling that something is being sold to them. When you observe photodamaged skin on a patient's hands, conversationally mention hand rejuvenation during the visit. One of the most natural ways to begin the conversation for hand rejuvenation is during treatment of other body locations, specifically the face because many patients are inclined to treat other areas of the body when augmentation of the face is already underway. Addressing treatment of the hands in your dialogue is natural and often is welcomed by the patient. If you are ambitious, you can utilize 3-dimensional photography software to simulate anticipated aesthetic outcomes. (The September 2011 editorial in *Cosmetic Dermatology*[®] addresses the advantages and disadvantages of 3-dimensional photography.²⁾

From Derick Dermatology, Barrington, Illinois, and Crystal Lake, Illinois, as well as the Department of Dermatology, Feinberg School of Medicine, Northwestern University, Chicago, Illinois. The author reports no conflicts of interest in relation to this article.

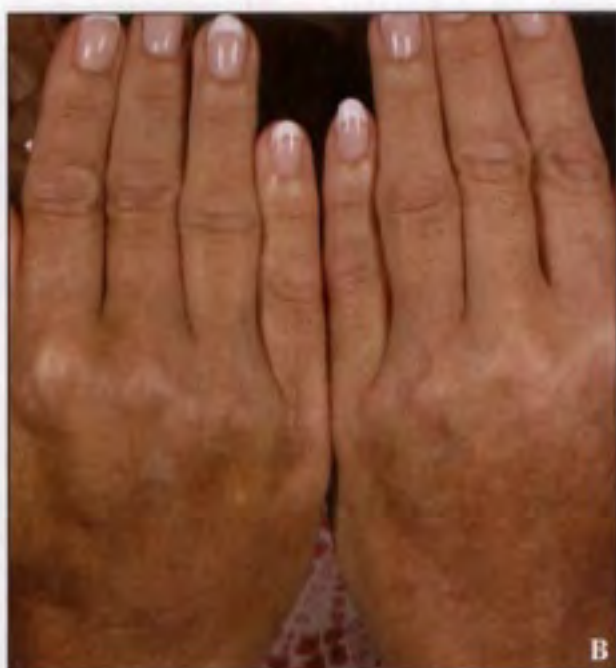
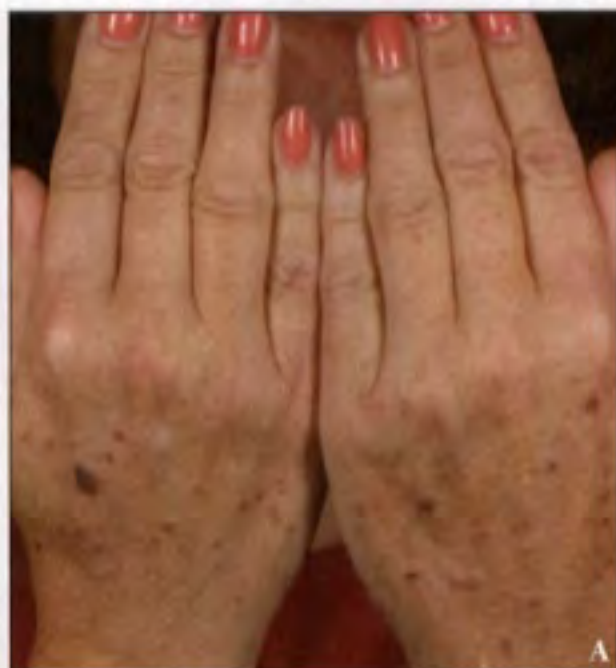
Figure 1. Hands with photodamage before (A) and after treatment with Q-switched alexandrite laser (755 nm), cryosurgery, and calcium hydroxylapatite filler (Radiesse, Merz Aesthetics, Inc)(B).

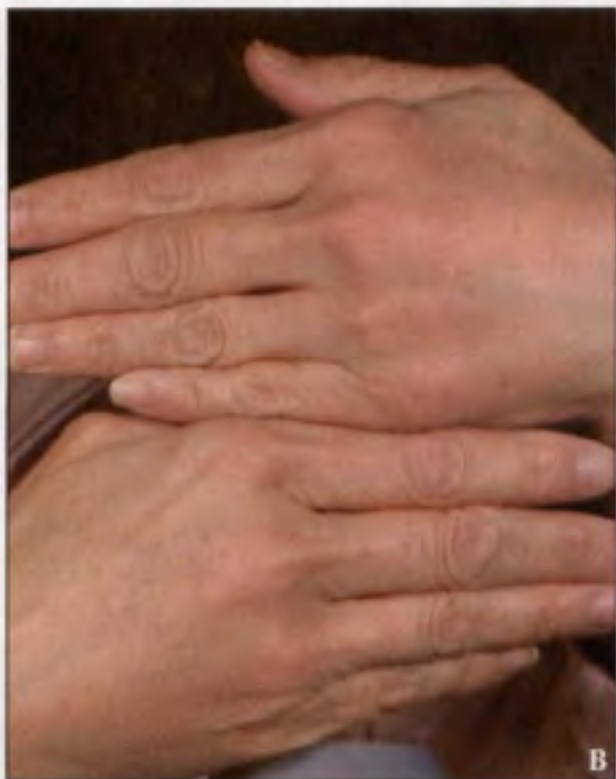
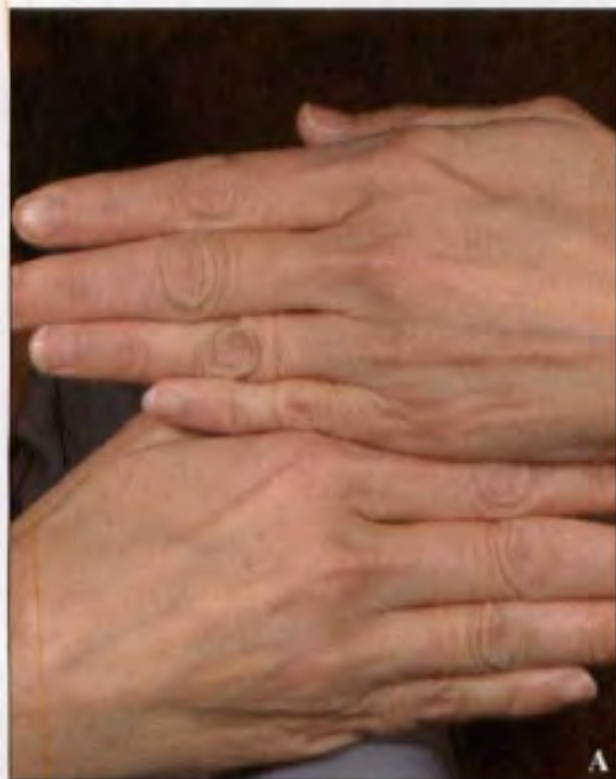
Figure 2. Hands before (A) and after treatment with calcium hydroxylapatite (Radiesse, Merz Aesthetics, Inc)(B).

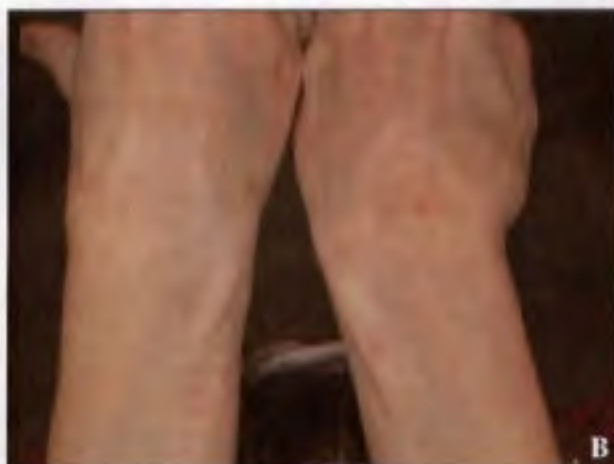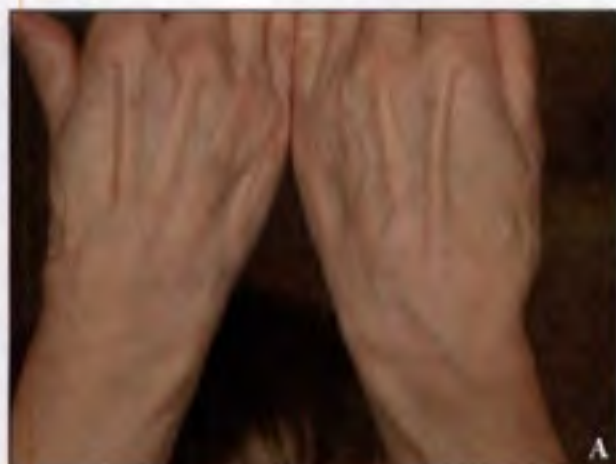


Figure 3. Hands before (A) and after treatment with calcium hydroxylapatite (Radiesse, Merz Aesthetics, Inc)(B).

Hand rejuvenation is a natural extension of facial rejuvenation; you simply have to connect the face and hands in your dialogue with patients. Some patients may want to start with treatment of the hands and then move on to the face, while other patients may prefer the opposite. In either case, patients will be pleased to know that cosmetic treatments exist for the hands, and you will naturally and pleasantly be able to increase average spending

by your patients while simultaneously improving patient satisfaction.

References

1. Fahi SG, Goldman MP: Hand rejuvenation: a review and our experience [published online ahead of print January 23, 2012]. *Dermatol Surg.* 2012;38(7, pt 2):1112-1127.
2. Denck A. Advantages and disadvantages of 3-dimensional photography for cosmetic procedures. *Cosmet Dermatol.* 2011;24:406-408. ■



Quick Poll Question

What percentage of your patients who receive facial augmentation also need treatment of the hands for pigmentation or volume correction?

- <10%
- 25%
- 50%
- >75%

Go to www.cosderm.com to answer our Quick Poll Question